

UDC 616.37-002-036.11-06-089-085.456.7

DOI <https://doi.org/10.32782/2786-9067-2026-31-1>

EARLY ENTERAL FEEDING IN SURGICAL TREATMENT OF ACUTE COMPLICATED PANCREATITIS

Andriushchenko D.V., Andriushchenko V.P., Prykopenko O.V.

State Nonprofit Company "Danylo Halytsky Lviv National Medical University", Lviv, Ukraine

Abstract. Aim – to evaluate the effectiveness of early enteral nutrition (EEN) in patients with acute complicated pancreatitis (ACP), including clarification of its therapeutic rationale and optimization of administration strategies.

Materials and Methods. The outcomes of EEN were analyzed in 82 patients with ACP, including 28(34%) with moderately severe disease and 54(66%) with severe disease. Two patient groups were identified: the main group (n=58), in whom EEN was implemented as a part of comprehensive treatment during preoperative and postoperative periods, and the comparison group (n=24), which received conventional treatment.

EEN was performed using various methods: placement of a probe during esophago-gastro-duodenoscopy into the proximal part of the small intestine (n=25), suboperative nasogastrintestinal intubation of the small intestine (n=12), and also the formation of a suspended jejunostoma according to Witzel technique (n=21).

*nutritional formulas were used in combination with the probiotic *Saccharomyces boulardii* (I-745) and the metabolic modulator – citrulline malate, including according to the original method. Commercially available enteral*

Results. The positive effect of the implemented EEN methods was manifested by a more rapid recovery of the motor-evacuatory function of the small intestine, normalization of leukocyte counts and blood protein levels, and attenuation of microstructural changes in the intestinal mucosa. In particular, a reduction in the number of necrotized villi was observed, from 16 (94%) to 5 (29%) ($\chi^2 = 12.454$; $p = 0.004$). Decreasing of the frequency of basal/apical enterocyte membrane detachment – from 15 (88%) to 6 (35%) ($\chi^2 = 7.971$; $p = 0.004$), and erosive changes – from 13 (76%) to 5 (29%) ($\chi^2 = 5.785$; $p = 0.01$) was observed, as well as cleansing of purulent-necrotic focus.

Conclusions. EEN represents an effective component of the surgical management of patients with ACP during both the preoperative and postoperative periods.

Enteral nutrition via Witzel-type jejunostomy demonstrated the highest efficacy and was fully aligned with contemporary principles of surgical patient management within «Fast-Track» – surgery.

Key words: acute complicated pancreatitis, early enteral nutrition

Introduction. Despite the fact that early EEF is a well-known component of treatment programs for acute complicated pancreatitis (ACP), a number of questions regarding the use of this method remains unclear [7; 8; 10; 11]. This concerns, in particular, the approach to its implementation method, the choice of nutritional mixtures for adequate nutritional support, effect evaluation on the recovery of digestive tract motor-evacuation function and levelling manifestations of enteral insufficiency [4; 12]. Therefore, the feasibility of using EEF in ACP requires further scientific-theoretical and practical-applied study.

Purpose. Evaluate the effectiveness of EEF in patients with ACP determining its content and improving implementation methods.

Materials and methods. EEF results were studied when used in a sample group of 82 patients with diagnosed ACP, who were on inpatient treatment in the City Pancreatic Centre at the Academic Department of General Surgery of the Danylo Halytsky National Medical University. In accordance with Atlanta Classification (2012) [3], moderately severe clinical course of disease was established in 28 patients (34%), severe – in 54 (66%). All patients were divided into two groups – the main group (58 patients) receiving EEF as a part of complex treatment in pre- and postoperative periods, and comparison group (24 patients) receiving treatment program based on traditional approaches with no EEF. Both groups of subjects were comparable in terms of age, sex, severity of the disease, degree of

pancreatic lesion, parapancreatic/circumintestinal retroperitoneal fat. Surgical treatment for infected pancreatic necrosis and/or purulent-necrotic parapancreatitis/paracolicitis was performed in 48 patients from the main and 17 patients from comparison groups.

Various EEF techniques have been applied and analysed. The first option was to place the catheter with a diameter of 3 mm into the first part of small intestine under diagnostic EGDS followed by the introduction of nutritional mixtures through its lumen. This technique, which was used in 25 patients, was the best one in preoperative period, as well as in those patients who did not undergo surgical treatment.

The second method included nasogastrintestinal intubation of the small intestine during open surgery, which provided both decompression of the digestive canal in the early postoperative period and possibility for EEF. Feeding using this method was administered in 12 subjects.

The third option was implemented in 21 patients – after completion of the main stages of intervention, a Witzel's jejunal tube was formed in the projection of the left hypochondrium or below the mediastinal laparotomic access with duodenal catheter placement into intestine lumen at a depth of 20-30 cm (Fig. 1).

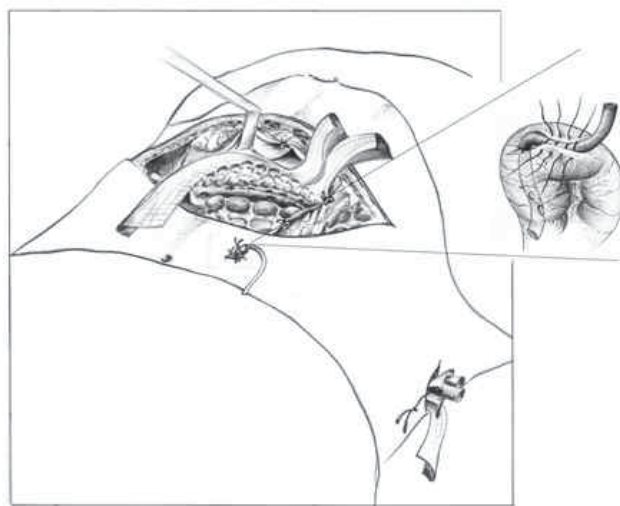


Fig. 1. Suspended jejunal tube

This method had a number of advantages, since did not cause discomfort in patients, did not limit their mobility and made impossible the probability of respiratory complications, which was completely in line with the Fast-track surgery principles [5; 6; 14]. This also created condition for a sufficiently long-term (up to 10-14 days) functioning of jejunal tube, and after catheter removing, the external intestinal fistula healed absolutely.

EEF effectiveness was evaluated based on dynamics analysis of the clinical manifestations of digestive tract motor and evacuation function impairment, laboratory and biochemical test parameters, dynamics of mucosa microstructural changes according to pathological findings, as well as suboperative characteristics of the purulent necrotic inflammatory foci. The obtained results were processed using variation statistics methods with Student's test, Fisher LSD and χ^2 .

Results. EEF was performed in accordance with the European Society for Parenteral and Enteral Nutrition recommendations (ESPEN, 2020,2024) [1; 2] and implemented in accordance with the developed composition and sequence of components use, which included the primary intraluminal drip infusion with NaCl physiological and hypertonic solutions, followed by the administration of officinal calorage-balanced nutritional mixtures at the first signs of peristalsis recovery, as well as

Saccharomyces boulardii probiotic (I-745) 250 mg in order to normalize obligate gutflora and levelling excessive colonization of the proximal small intestine with pathogenic microflora. The bolus administration method was mainly implemented, 150-200 ml of nutritional mixture per session for 20-30 minutes several times a day using a syringe or gravity feed. Prolonged EEF used enteral feedingsystems and special containers. The daily calorage of nutritional support was not less than 1900 – 2300 Kcal, which provided the optimum need of patient's body in nutrients. In order to increase EEF effectiveness the «Metabolic care methodin the postoperative period in patients with purulent-inflammatory pancreaticobiliary lesions» was used based oninternal probe applicationwith medicinal agent/metabolic care agent – Citrulline Malate.

Dynamics analysis of intestine motor and evacuation dysfunction showed thatdyspeptic events-resolved completely in patients of the main group on Day 3, abdominal distension resolved and peristalsis recovered. Instead, these events in the comparison groupwere not levelled within the same period. EEF also showed a significant trend towards leukocytosis normalization on Day 3 ($p < 0.05$). Plasma protein content in the main group increased significantly on Day 7 ($p < 0,05$), while in subjects of comparison group, no significant increase in protein during this period was observed.

Analysis of microstructural mucosal abnormalities of the firstpart of small intestine (as the morphological basis of enteral insufficiencysyndrome) according to pathohistological examination of biopsy material with dynamic EGDS in 28 patients, of which 17 patients with EEF and 11 patients with no nutritional support, allowed concluding that after enteral nutrition the number of patients with available manifestations of gut wall changes, both individually and in general, decreased significantly (Table 1).

Table 1

Dynamics of pathomorphological changes of the small intestinemucoas membrane

Nature of pathomorphological abnormalities	Main group		Comparisongroup	
	EEF start n (%)	Treatment completion n (%)	EEF start n (%)	Treatment completion n (%)
Mucosal villi necrosis	16 (94%)	5 (29%)	9 (82%)	7 (64%)
Basal/apical membrane detachment	15 (88%)	6 (35%)	10 (91%)	7(64%)
Swelling of the villi distal part	17 (100%)	4 (24%)	11 (100%)	6 (55%)
Epithelium scaling	8 (47%)	5 (29%)	5 (45%)	4 (36%)
Mucosal erosive changes	13 (76%)	5 (29%)	7 (64%)	6 (55%)

Thus, in the main group, the incidence of necrotized mucosal villi decreased significantly from 16 (94%) to 5 (29%) ($\chi^2 = 12.454$; $p = 0.004$), while in the comparison group such dynamics was not observed – from 9 (82%) to 7 (64%) cases ($\chi^2 = 0.229$; $p > 0.05$). During EEF implementation, the number of reported basal/apical membrane detachmentdecreased from 15 (88%) to 6 (35%) ($\chi^2 = 7,971$; $p = 0.004$), while in the comparison group, this pattern was not observed – 10 (91%) and 7 (64%) cases ($\chi^2 = 1,035$; $p > 0,05$). The same trend was observed with thelevelling dynamics of mucosal erosive changes – 13 (76%) vs 5 (29%) – $\chi^2 = 5,785$; $p = 0.01$ and 7 (64%) vs 6 (55%) – $\chi^2 = 0.188$; $p > 0.05$.

Sub-operative assessment of changesin the purulent-necrotic inflammation foci of the pancreas and retroperitoneal space tissues during implementation of stage lavage by means of relaparotomy (RLT) showed that EEF resulted in earlier “cleansing” of purulent necrotic areas from devitalised tissue, inflammatory exudate and purulence with reparative processes in the form of granulation tissue formation and absence of secondary infection. This provided the basis for switching to H. Beger method of closed flow-washing drainage, while in comparison group, no optimal cleansing of the inflammation foci was observed with repeated RLT during the same period.

Discussion. Although the major guidelines of the International Association of Pancreatologists (2013) declared the advisability of nutritional support in ACP patients through tube enteral feeding [15] and the American Commission of Gastroenterologists (2013) recommendations state that enteral feeding in severe ACP is indicated for nutritional support and prevention of developing infectious complications [12], however, a sufficiently large number of scientific publications evidences the lack of unambiguous approaches in assessing the theoretical and practical issues of this method effectiveness [9; 13; 16]. Studied EEF approach in ACP contributes greatly to addressing this issue.

Conclusions:

1. EEF in ACP patients with moderately severe and severe clinical course of the disease is an effective component of surgical treatment in pre- and postoperative periods.
2. EEF method using the sub-operatively formed suspended jejunal tube is the best confirmed method and corresponds completely to the “Fast-track” surgery principle.
3. It is advisable to include probiotics and metabolic care agents in addition to official nutritional mixtures as part of EEF composition.

Bibliography

1. Arvanitakis M., Ockenga J., Bezmarevic M., Gianotti L., Krznarić Ž., Lobo D. N., Löser C., Madl C., Meier R., Phillips M., Rasmussen H. H., VanHooft J. E., Bischoff S. C. ESPEN guideline on clinical nutrition in acute and chronic pancreatitis. *Clinical Nutrition*. 2020. Vol. 39, No. 3. P. 612–631. DOI: 10.1016/j.clnu.2020.01.004.
2. Arvanitakis M., Ockenga J., Bezmarevic M., Gianotti L., Krznarić Ž., Lobo D. N., Löser C., Madl C., Meier R., Phillips M., Rasmussen H. H., VanHooft J. E., Bischoff S. C. ESPEN practical guideline on clinical nutrition in acute and chronic pancreatitis. *Clinical Nutrition*. 2024. Vol. 43, No. 2. P. 395–412. DOI: 10.1016/j.clnu.2023.12.019.
3. Banks P. A., Bollen T. L., Dervenis C., Gooszen H. G., Johnson C. D., Sarr M. G. et al. Classification of acute pancreatitis–2012: revision of the Atlanta classification and definitions by international consensus. *Gut*. 2013. Vol. 62. P. 102–111. DOI: 10.1136/gutjnl-2012-302779.
4. Barreto S. G., Habtezion A., Gukovskaya A., Lugea A., Jeon C., Yadav D. et al. Critical thresholds: key to unlocking the door to the prevention and specific treatments for acute pancreatitis. *Gut*. 2021. Vol. 70, No. 1. P. 194–203. DOI: 10.1136/gutjnl-2020-322163.
5. Carli F., Kehlet H., Baldini G., Steel A., McRae K., Slinger P., Hemmerling T., Salinas F., Neal J. M. Evidence basis for regional anesthesia in multidisciplinary fast-track surgical care pathways. *Regional Anesthesia and Pain Medicine*. 2011. Vol. 36. P. 63–72. DOI: 10.1097/AAP.0b013e31820307f7.
6. Carter J., Philp S., Arora V. Early discharge after major gynaecological surgery: advantages of fast track surgery. *Open Journal of Obstetrics and Gynecology*. 2011. Vol. 1. P. 1–5. DOI: 10.4236/ojog.2011.11001.
7. Chan K. S., Shelat V. G. Diagnosis, severity stratification and management of adult acute pancreatitis: current evidence and controversies. *World Journal of Gastrointestinal Surgery*. 2022. Vol. 14. P. 1179–1197. DOI: 10.4240/wjgs.v14.i11.679.
8. Freeman M. L., Werner J., van Santvoort H. Intervention for necrotizing pancreatitis: summary of multidisciplinary consensus conference. *Pancreas*. 2012. No. 8. P. 1176–1194. DOI: 10.1097/MPA.0b013e318269c660.
9. Jaan A., Malik S., McFarland J. E., Olson E. T., Cryer B. Impact of ethnicity on the outcomes of acute pancreatitis: insights from US National Inpatient Sample. *Journal of Pancreatology*. 2024. Vol. 7. P. 86–89. DOI: 10.1097/jp9.000000000000149.
10. Leppäniemi A., Tolonen M., Tarasconi A. et al. WSES guidelines for the management of severe acute pancreatitis. *World Journal of Emergency Surgery*. 2019. Vol. 14. P. 27. DOI: 10.1186/s13017-019-0247-0.
11. Sartelli M., Chichom-Mefire A., Labricciosa F. et al. The management of intra-abdominal infections from a global perspective: 2017 WSES guidelines. *World Journal of Emergency Surgery*. 2017. Vol. 12. P. 29. DOI: 10.1186/s13017-017-0141-6.

12. Scott T., Baillie J., DeWitt J. American College of Gastroenterology guideline: management of acute pancreatitis. *American Journal of Gastroenterology*. 2013. Vol. 108, No. 9. P. 1400–1416. DOI: 10.1038/ajg.2013.218.

13. Trikudanathan G., Yazici C., Evans Phillips A., Forsmark C. E. Diagnosis and management of acute pancreatitis. *Gastroenterology*. 2024. Vol. 167. P. 673–688. DOI: 10.1053/j.gastro.2024.02.052.

14. Wind J., Polle S. W., Fung Kon Jin P. H. et al. Systematic review of enhanced recovery programmes in colonic surgery. *British Journal of Surgery*. 2006. Vol. 93. P. 800–809. DOI: 10.1002/bjs.5384.

15. Working Group IAP/APA Acute Pancreatitis Guidelines. IAP/APA evidence-based guidelines for the management of acute pancreatitis. *Pancreatology*. 2013. Vol. 13, No. 4 (Suppl. 2). P. e1–e15. DOI: 10.1016/j.pan.2013.07.063.

16. Yang D., Zhang F., Bai L., Wang X. Alcoholic and non-alcoholic acute pancreatitis mortality in the United States, 2006–2023: a nationwide trend analysis. *Scientific Reports*. 2026. DOI: 10.1038/s41598-026-37268-6.

References

1. Arvanitakis, M., Ockenga, J., Bezmarevic, M., Gianotti, L., Krznarić, Ž., Lobo, D. N., Löser, C., Madl, C., Meier, R., Phillips, M., Rasmussen, H. H., VanHooft, J. E., & Bischoff, S. C. (2020). ESPEN guideline on clinical nutrition in acute and chronic pancreatitis. *Clinical Nutrition*, 39(3), 612–631. <https://doi.org/10.1016/j.clnu.2020.01.004>

2. Arvanitakis, M., Ockenga, J., Bezmarevic, M., Gianotti, L., Krznarić, Ž., Lobo, D. N., Löser, C., Madl, C., Meier, R., Phillips, M., Rasmussen, H. H., VanHooft, J. E., & Bischoff, S. C. (2024). ESPEN practical guideline on clinical nutrition in acute and chronic pancreatitis. *Clinical Nutrition*, 43(2), 395–412. <https://doi.org/10.1016/j.clnu.2023.12.019>

3. Banks, P. A., Bollen, T. L., Dervenis, C., Gooszen, H. G., Johnson, C. D., Sarr, M. G., et al. (2013). Classification of acute pancreatitis–2012: Revision of the Atlanta classification and definitions by international consensus. *Gut*, 62, 102–111. <https://doi.org/10.1136/gutjnl-2012-302779>

4. Barreto, S. G., Habtezion, A., Gukovskaya, A., Lugea, A., Jeon, C., Yadav, D., et al. (2021). Critical thresholds: Key to unlocking the door to the prevention and specific treatments for acute pancreatitis. *Gut*, 70(1), 194–203. <https://doi.org/10.1136/gutjnl-2020-322163>

5. Carli, F., Kehlet, H., Baldini, G., Steel, A., McRae, K., Slinger, P., Hemmerling, T., Salinas, F., & Neal, J. M. (2011). Evidence basis for regional anesthesia in multidisciplinary fast-track surgical care pathways. *Regional Anesthesia and Pain Medicine*, 36, 63–72. <https://doi.org/10.1097/AAP.0b013e31820307f7>

6. Carter, J., Philp, S., & Arora, V. (2011). Early discharge after major gynaecological surgery: Advantages of fast track surgery. *Open Journal of Obstetrics and Gynecology*, 1, 1–5. <https://doi.org/10.4236/ojog.2011.11001>

7. Chan, K. S., & Shelat, V. G. (2022). Diagnosis, severity stratification and management of adult acute pancreatitis: Current evidence and controversies. *World Journal of Gastrointestinal Surgery*, 14, 1179–1197. <https://doi.org/10.4240/wjgs.v14.i11.679>

8. Freeman, M. L., Werner, J., & van Santvoort, H. (2012). Intervention for necrotizing pancreatitis: Summary of multidisciplinary consensus conference. *Pancreas*, 41(8), 1176–1194. <https://doi.org/10.1097/MPA.0b013e318269c660>

9. Jaan, A., Malik, S., McFarland, J. E., Olson, E. T., & Cryer, B. (2024). Impact of ethnicity on the outcomes of acute pancreatitis: Insights from US National Inpatient Sample. *Journal of Pancreatology*, 7, 86–89. <https://doi.org/10.1097/jp9.0000000000000149>

10. Leppäniemi, A., Tolonen, M., Tarasconi, A., et al. (2019). WSES guidelines for the management of severe acute pancreatitis. *World Journal of Emergency Surgery*, 14, 27. <https://doi.org/10.1186/s13017-019-0247-0>

11. Sartelli, M., Chichom-Mefire, A., Labricciosa, F., et al. (2017). The management of intra-abdominal infections from a global perspective: 2017 WSES guidelines. *World Journal of Emergency Surgery*, 12, 29. <https://doi.org/10.1186/s13017-017-0141-6>

12. Scott, T., Baillie, J., & DeWitt, J. (2013). American College of Gastroenterology guideline: Management of acute pancreatitis. *American Journal of Gastroenterology*, 108(9), 1400–1416. <https://doi.org/10.1038/ajg.2013.218>
13. Trikudanathan, G., Yazici, C., Evans Phillips, A., & Forsmark, C. E. (2024). Diagnosis and management of acute pancreatitis. *Gastroenterology*, 167, 673–688. <https://doi.org/10.1053/j.gastro.2024.02.052>
14. Wind, J., Polle, S. W., Fung Kon Jin, P. H., et al. (2006). Systematic review of enhanced recovery programmes in colonic surgery. *British Journal of Surgery*, 93, 800–809. <https://doi.org/10.1002/bjs.5384>
15. Working Group IAP/APA Acute Pancreatitis Guidelines. (2013). IAP/APA evidence-based guidelines for the management of acute pancreatitis. *Pancreatology*, 13(4 Suppl 2), e1–e15. <https://doi.org/10.1016/j.pan.2013.07.063>
16. Yang, D., Zhang, F., Bai, L., & Wang, X. (2026). Alcoholic and non-alcoholic acute pancreatitis mortality in the United States, 2006–2023: A nationwide trend analysis. *Scientific Reports*. <https://doi.org/10.1038/s41598-026-37268-6>

РАННЄ ЕНТЕРАЛЬНЕ ХАРЧУВАННЯ В ХІРУРГІЧНОМУ ЛІКУВАННІ ГОСТРОГО УСКЛАДНЕНОГО ПАНКРЕАТИТУ

Андрющенко Д.В., Андрющенко, В.П., Прикупенко О.В.

Анотація. Мета – здійснити оцінку ефективності раннього ентерального харчування (РЕХ) у хворих на гострий ускладнений панкреатит (ГУП) з визначенням його змісту та вдосконаленням методик реалізації.

Матеріали та методи. Вивчено результати РЕХ у 82 хворих на ГУП з помірно-тяжким (28; 34%) та тяжким (54; 66%) клінічним перебігом захворювання. Виокремлено дві групи пацієнтів – основну (58), у комплексі лікування котрих реалізовувалось РЕХ у до- та післяопераційному періодах і порівняльну (24) з традиційними лікувальними підходами. РЕХ проводилось з використанням різних методик, а саме, шляхом встановлення зонду при езофаго-гастро-дуоденоскопії в початковий відділ тонкої кишки (25), під час виконання субопераційної назо-гастроінтестинальної інтубації кишки (12), а також в процесі формуванні підвісної єюностоми за Вітцелем (21). Використовувалися офіційна харчові суміші в поєднанні з пробіотиком *Saccharotusces boulardii* (I-745) та коректором метаболізму – малат цитруліном, в тому числі і за оригінальним способом.

Результати. Позитивний ефект реалізованих методик РЕХ проявлявся у більш швидкому відновленні моторно-евакуаторної функції тонкої кишки, нормалізації показників лейкоцитозу та рівня білків крові, нівелюванні мікроструктурних змін слизової оболонки кишкового тракту, зокрема у зменшенні некротизованих ворсинок з 16 (94%) до 5 (29%) ($\chi^2=12,454$; $p=0,004$), частоти відшарувань базальної/апикальної мембрани ентероцитів з 15 (88%) до 6 (35%) ($\chi^2=7,971$; $p=0,004$) та ерозивних змін з 13 (76%) до 5 (29%) ($\chi^2=5,785$; $p=0,01$), а також в «очищенні» ділянок гнійно-некротичного осередку.

Висновки. РЕХ є ефективним компонентом хірургічного лікування хворих на ГУП у до- та післяопераційному періодах. Спосіб харчування через підвісну єюностому за Вітцелем виявився найбільш ефективним і таким, що в повній мірі відповідав сучасним принципам ведення хірургічних пацієнтів – «Fast-track» – хірургії.

Ключові слова: гострий ускладнений панкреатит, раннє ентеральне харчування,

Андрющенко Дмитро Вікторович, ORCID: <https://orcid.org/0000-0003-1046-7889>

Андрющенко Віктор Петрович, ORCID: <https://orcid.org/0000-0003-1848-7358>

Прикупенко Олена Вікторівна, ORCID: <https://orcid.org/0009-0008-2584-0010>

